

Considerations for the use of ultrasound in the developing world during the COVID-19 pandemic

It is an unprecedented time in healthcare, challenging the needs of every system to find a way to manage limited resources, protect the safety of patients and healthcare teams while remaining innovative to meet the ongoing needs of each community. This scenario, while unique to most current American health care systems, is a daily struggle for many low and middle-income countries globally. For healthcare systems in these areas, dealing with lack of infection control, diminished resources, lack of education and reduced access to imaging and other diagnostics is a way of life.

Ultrasound continues to be extremely valuable in the diagnosis and management of many clinical scenarios. It has become especially powerful in low resource areas due to its lack of ionizing radiation, portability, affordability and diverse uses both therapeutic and diagnostic. During this time, it is expected that questions surrounding the use of ultrasound in the setting of COVID-19 would emerge specifically reviewing the specificity and sensitivity of lung ultrasound exams.

To best address this question, we have taken time to review a large number of resources available discussing the use of ultrasound. Well-known resources on lung ultrasound exams exist beginning with Lichtenstein's seven principles of lung ultrasound in the critically ill patient.⁽¹⁾ Much of the current literature on lung ultrasound comes from experiences had by medical staff in Italy and China largely, with point-of-care ultrasound. However, it is important to note that most studies suffer from a very small sample size making application to current practice challenging. In addition, some resources are vendor specific and may influence recommendations.

The overall volume of material available is a bit overwhelming and the information being shared is dynamic, however, common themes and recommendations persist. The information is found in multiple formats including videos, PowerPoint presentations, scientific journals, articles, case studies, opinion pieces, along with numerous images and statements from well-known and reviewed sources like American College of Radiology (ACR), American Institute of Ultrasound in Medicine (AIUM), Center for Disease Control (CDC) and World Health Organization (WHO). It is our intention to share materials reviewed by our subject matter experts with extensive experience providing ultrasound imaging and ultrasound education in the developing world. We hope to provide support to our teams and country partners working to optimize their resources and protect their patients and staff.

The resources we will share below are not intended to be, nor offered as comprehensive medical guidelines in regard to radiologic imaging in the setting of COVID, but may be of help to the radiologic community in the developing world as we all work to protect patients and health care workers from the virus. Ultimately, healthcare teams and leadership will have to work together to make the decision that is best for their practice based on their current resources, patient population and access to diagnostics, treatment options,

available PPE and ability to maintain infection control practices. While there is no cure for COVID-19 and symptomatic management is the mainstay, many countries lack access to medications, ventilators and capacity to handle even small volumes of infected patients.

OBJECTIVES

- Lung ultrasound and other radiologic studies cannot be used to diagnose COVID-19, as it remains a clinical diagnosis.
- Small cohorts have used lung ultrasound in the clinical management of COVID positive patients, but definitive guidelines for use do not exist.
- Lung ultrasound is a portable resource that can be useful to triage and monitor a variety of lung processes and may be helpful when chest x-ray or CT is unavailable.
- A thorough understanding of lung ultrasound windows, protocols, and useful artifacts as well as appropriate ultrasound equipment is required to perform lung ultrasound.
- Adequate PPE and disinfection must be available for staff performing lung ultrasound and exposure to positive COVID patients should be minimized.
- Resources utilized for lung ultrasound education must be from reliable sources and users should have an adequate understanding and skill set to perform lung ultrasound.

CLINICAL CONSIDERATIONS

COVID-19 is a clinical diagnosis. There is no radiologic study that can definitively diagnose the virus without viral testing to confirm. The American College of Radiology stated on March 11, “The CDC does not recommend chest x-ray or CT to diagnose COVID-19, viral testing remains the only specific method of diagnosis. Confirmation with the viral test is required, even if radiologic findings are suggestive of COVID-19 on chest x-ray or CT.” ⁽²⁾) At this time, there are no definitive guidelines or recommendations for the use of ultrasound in the clinical management of this virus.

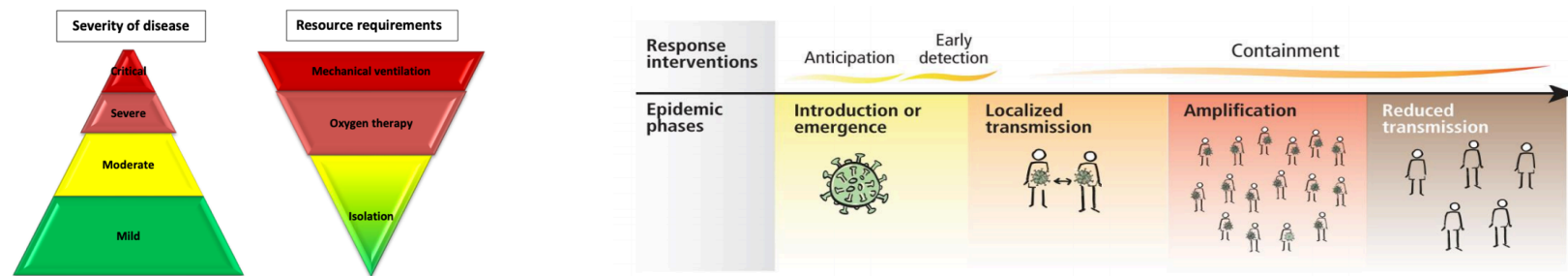
Patients typically present with fever, cough and shortness of breath (SOB). Risk factors include known COVID contact or return from high-risk area. Per CDC recommendations, patients and care teams can be prioritized in regard to care and testing. Consider triage of:

1. inpatients and healthcare workers (HCW) with symptoms
2. patients in long-term care facilities, older than 65, having comorbid conditions including HTN, T2DM, CVD, CRD, and immunity issues
3. first responders with symptoms
4. individuals that comprise a critical part of the patient care infrastructure

5. individuals with mild symptoms in a community with high incidence of COVID patients

This order for triage optimizes care for patients, decreases risk of HCAI and maintains the integrity of the health care system. Furthermore, it protects those at highest risk for complications, and allows for optimum use of resources to decrease community spread and ensure health of essential workers.

Consider the following diagram provided by the WHO in regard to disease severity and resource requirements as it relates to COVID-19. This information is relevant to challenged health care systems with the primary goals being prevention of outbreak, delay of spread, optimization of care for all patients and minimizing the impact of the epidemic on health care systems, social services and economics.



Thus far, data suggests that around 40% of cases are mild requiring symptomatic management, another 40% are moderate and may provide inpatient care, 15% are severe requiring oxygen therapy and inpatient care, with the remaining 5 % as critical and necessitating mechanical ventilation. However, the outbreak in some countries has shown a higher proportion of severe and critical cases leading to rapid use of biomedical supplies and increased demands on staffing. in some areas, doubling rates of cases every three days has been observed. ⁽³⁾

LITERATURE REVIEW

In regard to the use of ultrasound to evaluate the lung, there is extensive literature and discussions about its utility, sensitivity and specificity, suggested protocols and the ultrasound signs characteristic of certain diseases, the most applicable in this case being pneumonia. This section will review recent relevant publications and highlight the key points of each.

Article Title	Link	Key points
COVID-19 outbreak: less stethoscope, more ultrasound Buonsenso et al The Lancet: Respiratory Medicine	https://www.thelancet.com/journals/lanres/article/PIIS2213-2600(20)30120-X/fulltext	<ol style="list-style-type: none"> 1. Minimize HCW's exposure by performing only necessary ultrasound exams at this time. 2. Lung ultrasound is accurate in detection of pathology associated with bacterial and viral pneumonia, ARDS, pneumothorax, and pleural effusions 3. Bringing ultrasound to the bedside can minimize patient exposure within radiology suite.
Lung Ultrasound Wong et al British Medical Ultrasound Society	https://www.bmus.org/static/uploads/resources/COVID19_Lung_Ultrasound_BMUS.pdf	<ol style="list-style-type: none"> 1. COVID-19 is a clinical diagnosis 2. Lung ultrasound exam should be used in conjunction with clinical correlation 3. Lung ultrasound should not be attempted by novice scanners, intricate exam to perform 4. The necessity of ultrasound should be verified and avoided if no change in patient clinical management is anticipated 5. Lung ultrasound can be useful for problem solving, finding alternative diagnosis, defining disease extent, guiding response to therapy and timing to wean mechanical ventilation 6. Ultrasound without means of managing findings could be considered misuse of resources.
Findings of lung ultrasonography of novel coronavirus pneumonia during the 2019-2020 epidemic <i>Intensive Care Medicine.</i>	https://link.springer.com/article/10.1007/s00134-020-05996-6#Sec1	<ol style="list-style-type: none"> 1. Experiences from Italy and China demonstrate ultrasound can be helpful in three key clinical areas: Distinguish causes of dyspnea; monitoring treatment response, done easily at the bedside 2. Sensitivity to disease detection rivals CT 3. Cautions for utilization of lung ultrasound include, necessary governance, avoid over-calling interpretations, using imaging in clinical context 4. Utilization of other imaging modalities and serologic testing <i>is necessary</i> for verifying.
Diagnostic use of lung ultrasound compared to chest radiograph for suspected pneumonia in a resource-limited setting. International Journal of Emergency Medicine Amatya et al	https://www.ncbi.nlm.nih.gov/pubmed/29527652	<ol style="list-style-type: none"> 1. Specific discussions in regard to lung ultrasound include probe selection, technical approach and comparing findings to other modalities 2. Findings include: CXR is less sensitive than lung ultrasound exam, however lung ultrasound comparable to Chest CT for sensitivity of disease detection 3. Lung ultrasound sensitivity in disease detection is dependent on disease severity, patient body habitus, and patient ability to tolerate the exam and scanning techniques. 4. Lung ultrasound exam limitations include missing disease deep in the parenchyma that does not extend to the pleura 5. Lung ultrasound is not specific, and interpretation of the exam can be difficult in the presence of TB or COPD. 6. Lung ultrasound findings are not specific as certain findings seen in COVID can also be seen in pneumonia of interstitial lung disease.

Is There a Role for Lung Ultrasound During the COVID-19 Pandemic Journal of Ultrasound in Medicine	https://onlinelibrary.wiley.com/doi/epdf/10.1002/jum.15284 Journal of Ultrasound Med 2020, 9999:1-4	<ol style="list-style-type: none"> 1. Concur with view that various types of ultrasound artifacts can be leveraged to identify alterations to subpleural tissue. 2. Lung ultrasound exams allow providers to characterize findings from normal to consolidative document images for evaluation of regression or evolution of disease over time and triage patients with clinical symptoms which reduces exposures to other HCW
Radiology Business	https://www.radiologybusiness.com/to-pics/care-delivery/ct-scan-coronavirus-chest-x-ray-radiology-covid-19 3/11/20	<ol style="list-style-type: none"> 1. ACR: warns of overuse of CT or reliance on CXR to identify COVID-19 due to discordant findings between negative lab testing and positive CT findings. They also warn that not all published articles available are complete or up-to-date as this situation is rapidly evolving. 2. CDC: does not endorse CXR or CT to diagnose COVID-19. If CXR is to be used, perform portably to limit HCW infection risk. 3. CDC: Consideration should be given to the extensive cleaning required to maintain appropriate infection control of CT equipment, suite, ventilation, and airflow. Therefore, CT should be used sparingly, reserving the time for more appropriate patients. Understand that a abnormal CT <i>is not specific for COVID</i>. 4. No mention is made in regard to ultrasound and its applicability in the setting of COVID-19.

Ultrasound continues to gain attention in the healthcare arena with questions about its' utility in the clinical management of COVID-19. Certain inferences can be made based on POCUS lung ultrasound used in the setting of pneumonia where ultrasound artifacts are used to leverage information relevant to patient management. In a recent statement from the WHO, efforts should be directed towards coordination and planning for the epidemic, finding testing and care for suspected cases, and isolating cases while quarantine reduces contacts and controls transmission. This will require the engagement and mobilization of communities to limit exposure to the general population. We must provide clinical care and maintain essential health series to reduce mortality and adapt strategies based on risk, capacity and vulnerability and suppress community transmission. (4)

Operational Considerations

COVID-19 Ultrasound Guidelines

Sonographers are specially trained imaging personnel that, when ill, are taken out of patient care settings and are not easily replaced. If sonographers are not properly protected against COVID-19 or they do not adhere to set guidelines, the care of all ultrasound patients suffers a negative impact.

Use of Personal Protective Equipment (PPE)

A gown, medical mask, gloves, and eye protection⁽⁵⁾ should be worn for all suspected⁽⁶⁾ and all symptomatic patients should be considered COVID-19 negative.^(7,8) Use of PPE (mask and eye protection)⁽⁹⁾ should be extended as may be used for more than 1 patient of same status (Table 1).⁽⁹⁾ PPE may be life/expiration date⁽⁹⁾ (medical mask/eye protection = good condition (no tears) = good condition, perform seal check⁽⁹⁾).

Table 1	
Confirmed→	Confirmed
Suspected→	Suspected
Negative→	Negative

patients (confirmed and infected until testing long as possible and used beyond shelf⁽⁹⁾; respirator N95/FFP2

Hand hygiene should be performed before and after patient contact as well as before and after removing PPE.⁽⁹⁾ Options include an alcohol based hand rub of 60-95% alcohol or soap and water for at least 20 seconds.^(7,10)

Exposure

Consideration should be taken to minimize staff exposure to COVID-19 patients⁽⁵⁾ and sonographers with specific health problems should limit exposure to these patients.⁽⁷⁾ Departments can consider designating staff to image COVID-19 patients or limit the number of staff in contact with COVID-19 suspected or confirmed patients.⁽⁹⁾ Limiting staff in contact with these patients will extend PPE longer,⁽⁹⁾ streamline workflow and protocols to reduce direct contact time,⁽⁹⁾ and preserve healthy staff for other patient care or to move into roles as designated staff for COVID-19 patients as need arises.

Ultrasound exams, including lung ultrasound, should be limited to urgent and emergent cases only⁽⁷⁾ and decisions of elective vs urgent vs emergent cases can be made locally.⁽⁶⁾ Departments should plan what exams will and will not be performed and patient imaging should occur at the bedside whenever possible.⁽⁹⁾ With the proper equipment and resources, lung ultrasound for COVID-19 may be used to triage (not diagnose) symptomatic patients, manage intensive care patients with regard to ventilation or weaning, and to monitor the effects of therapy.⁽¹¹⁾

No visitors, except those essential to the care of a patient, should be allowed near sonographers during exams.⁽⁷⁾ In work areas, sonographers should maintain physical distance (1 meter) from others⁽⁹⁾ and consider wearing a medical mask, if available.

Equipment

Departments should dedicate systems and transducers for COVID-19 patients^(12,8,6) and only use necessary transducers for the exam.⁽⁶⁾ Gel use should include single-use packets, if available, which should be discarded after use.⁽⁶⁾ Multi-use gel bottles may also be used and should be low-level disinfect after the exam.⁽⁶⁾ Recommended barrier devices like transducer covers, medical gloves or other physical barriers for the transducers and console should be used whenever possible but are not required.⁽¹²⁾ Portable and hand-held

ultrasound devices are ideal for bedside ultrasound exams and are easier to disinfect after exposure.^(13, 6) A hand-held ultrasound device should be covered entirely with a barrier, if available.^(13,6)

Disinfection [low-level (LLD) and high-level (HLD)]

Sonographers should routinely clean and LLD disinfect surfaces in contact with COVID-19 patients⁽¹⁴⁾ such as machines, transducers, gel bottles, and other room equipment.⁽⁷⁾ Even when using a barrier device, transducers should be disinfected after the barrier device is removed.⁽⁶⁾ HLD should be considered, when available, if the transducer is in contact with non-intact skin, body fluids, blood, or mucous membranes, even if using a barrier device.⁽⁶⁾

While ultrasound exams should be performed at the bedside whenever possible, the following guidelines should be observed if a COVID-19 patient is in an ultrasound exam room. Refrain from using the exam room for at least 45 minutes and up to 70 minutes time after the patient vacates the room^(10, 8) and clean equipment after elapsed time.^(10, 8) Proper PPE must be used during disinfection of the equipment and room.⁽⁶⁾

Available disinfection products and solutions may vary by region and include low-level and high-level options. Low-level disinfectants may include 70% ethyl alcohol⁽¹⁵⁾ and chlorine-based solution of 1,000ppm minimum⁽¹⁶⁾ and high-level disinfection options may include 2.4-3.2% glutaraldehyde (Cidex, Metricide, Procide)⁽⁶⁾, non-glutaraldehyde agents (Cidex OPA, Cidex PA)⁽⁶⁾, chlorine dioxide (Tristel Duo)^(17, 6), and 7.5% hydrogen peroxide solution.⁽⁶⁾ Soap and water is an alternative low-level disinfection option if no other option exists.⁽¹²⁾ Depending on available options, care should be taken to compare equipment manufacturer guidelines with available disinfectants to avoid equipment damage or voiding warranties due to improper product use.

Educational Resources reviewing Lung Ultrasound

Overview:

This list of educational material covers a wide spectrum of information on lung ultrasound exams, diagnostic criteria for interpretation as well as differential diagnoses for abnormal imaging findings. There are numerous variations to the lung scanning protocol and scanning techniques and each have their own set of pros and cons, but the common theme is leveraging ultrasound artifacts to identify pathology and disease. Additionally, operator-dependence, infection control and lack of standardized education continue to be a concern.

Introduction to Lung Ultrasound Dr. Stella Savarimuthu and Dr. Cameron Baston	https://www.youtube.com/watch?v=rx_2C98js-l&t=22s	A beginner tutorial on how to perform a lung ultrasound exam, including equipment set up, probe orientation, and ultrasound terms. This video does NOT review a lung scanning protocol. It includes case studies to demonstrate how to use in conjunction with clinical symptoms.
Lung Ultrasound: 10 Basic Signs DR. Joshua M. Jacquet, RDMS, FACEP	https://www.youtube.com/watch?v=_Q0cTG3ZlHk&feature=youtu.be	This is an introductory video that reviews the 10 basic signs identified in lung ultrasound exam. This video will help the learners better understand the pathology discussed in other videos.
POCUS: Understanding B-Lines and Hepatization Dr. Jared T. Marx	https://www.youtube.com/watch?v=85v09M6oCMY	A good short introduction video for describing B lines and hepatization. Utilizes diagrams extensively and correlates to ultrasound cine clips and then includes multiple differential diagnoses. Also correlates radiology pathology terminology to the terms used in lung sonography.
Lung Ultrasound Common Pitfalls Katie Wiskar	https://www.youtube.com/watch?v=58kS_jrxIMl	Explains with both words and diagrams which scanning windows it will use in this lecture. transducer explanation, preset, scan depth, scan orientation and angle of insonation including demonstration. Explains difference between B and Z lines and how to differentiate. Really like the emphasis on correlation to clinical findings.
Point of Care Lung Ultrasound Dr. Michael B. Stone, RDMS	http://viewer.zmags.com/publication/1f3688e9#/1f3688e9/28	This is a PDF document that reviews all the basics of POCUS Lung exam. Good for beginners to lung ultrasound.
Basic Lung Ultrasound: Technique and Normal Findings Dr. Irene Ma, PhD, FRCPC, FACP	https://www.youtube.com/watch?v=RBgGA_rqVvE	Scanning technique and imaging protocol.
The Blue Protocol, Bedside Lung Ultrasound in Emergency Robert Kollpainter, PA-C, FAPACVS, RDMS, CAQ in CVTS	https://www.youtube.com/watch?v=CG5iglv5Azs	This video covers the BLUE protocol of POCUS lung exams. It offers a more in depth explanation with correlating diagrams, ultrasound cine clips, diagrams, and chest xrays. This video is good for understanding how lung artifacts are created and what they mean. It offers disease differential considerations. Demonstrates how to use the algorithm of the BLUE protocol to determine differential diagnosis of lung ultrasound findings.
Lung Ultrasound: Nuts & Bolts & COVID-19 Dr. Rachel Liu	https://www.youtube.com/watch?v=Z-zY_YdGHpA&feature=youtu.be	Excellent video of how to perform a lung ultrasound, including a live demonstration, review information relevant to COVID19.
Point of Care Ultrasound in COVID-19 Dr. Joe Minardi	https://www.youtube.com/watch?v=nx6eHINDveM&t=140s	A short but comprehensive review of performing a lung ultrasound exam includes information that pertains to COVID-19. Review of PPE, disinfection, and room set up.
Lung Ultrasound in COVID-19	https://www.youtube.com/watch?v=y5QJ5O3ldE0&feature	Good although very in-depth video that reviews equipment set up, and explanation of how to perform the exam. It also explains the difference between the BLUE protocol and the zone

DR. Joshua M. Jacquet, RDMS, FACEP	=youtu.be	approach to lung ultrasound exams. This video reviews imaging findings in CT and correlates to SARS, MERS, and COVID-19. Reviews and explains findings in recent publications. Best to watch this after the video on the Blue Protocol
Lung Ultrasound for Pulmonary COVID-19 Dr. Elke Platz, MS, FACEP, FESC	https://www.youtube.com/watch?v=EQtzCVMC_Dk	This video reviews cleaning and disinfection along with scanning protocol. Includes a review of very current literature on COVID19.
Peng,Q., Wang, X.& Zhang, L. Findings of lung ultrasonography of novel coronavirus pneumonia during the 2019-2020 epidemic. <i>Intensive Care Medicine</i> .	https://link.springer.com/article/10.1007/s00134-020-05996-6	

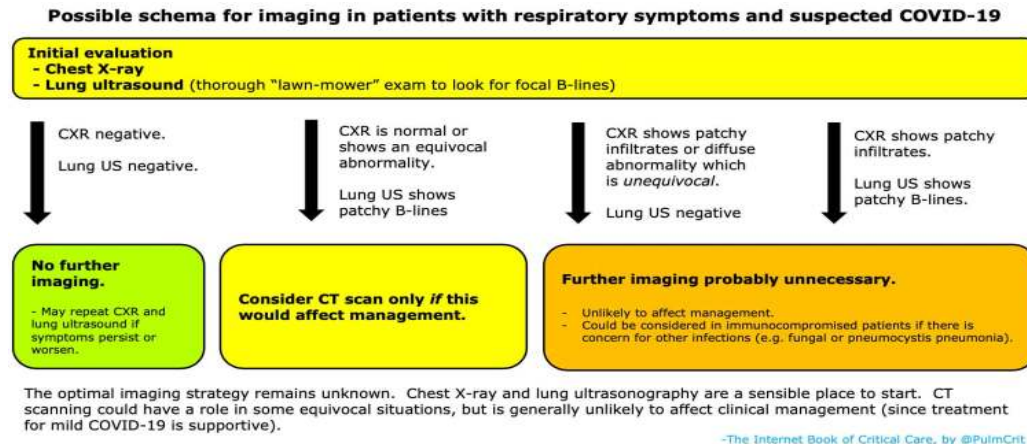
BIBLIOGRAPHY

1. Lichtenstein, D.A. Lung ultrasound in the critically ill. *Ann. Intensive Care* 4, 1 (2014). <https://doi.org/10.1186/2110-5820-4-1>
2. American College of Radiology *ACR Recommendations for the use of Chest Radiography and Computed Tomography (CT) for Suspected COVID-19 Infection* (March 22,2020) <https://www.acr.org/Advocacy-and-Economics/ACR-Position-Statements/Recommendations-for-Chest-Radiography-and-CT-for-Suspected-COVID19-Infection>
3. World Health Organization *Operational Considerations for case management of COVID-19 in health facility and community: Interim Guidance* (March 19 2020) https://apps.who.int/iris/bitstream/handle/10665/331492/WHO-2019-nCoV-HCF_operations-2020.1-eng.pdf
4. World Health Organization COVID-19 Strategy Update: Global Strategy to Respond to Covid-19 (April 14,2020) <https://www.who.int/publications-detail/covid-19-strategy-update---14-april-2020>
5. World Health Organization *Rational use of personal protective equipment (PPE) for coronavirus disease (COVID-19)* (March 19, 2020) https://apps.who.int/iris/bitstream/handle/10665/331498/WHO-2019-nCoV-IPCPPE_use-2020.2-eng.pdf
6. World Federation of Ultrasound in Medicine and Biology *How to perform a safe ultrasound examination and clean equipment in the context of COVID-19* (2020) https://wfumb.info/wp-content/uploads/2020/03/WFUMB-covid19-document_FINAL2d.pdf
7. American Institute of Ultrasound in Medicine *Quick Guide on COVID-19 Protections- Patient and Ultrasound Provider Protection* (2020) https://aium.s3.amazonaws.com/covid19/Covid19_Quick_Guide_PUPP.pdf
8. Centers for Disease Control and Prevention *Infection Control Guidance* (2020) <https://www.cdc.gov/coronavirus/2019-ncov/hcp/infection-control-recommendations.html>
9. World Health Organization *Rational use of personal protective equipment for coronavirus disease (COVID-19) and considerations during severe shortages* (April 6, 2020) https://apps.who.int/iris/bitstream/handle/10665/331695/WHO-2019-nCov-IPC_PPE_use-2020.3-eng.pdf
10. Centers for Disease Control and Prevention *Guidelines for Environmental Infection Control in Health-Care Facilities* (2003) <https://www.cdc.gov/infectioncontrol/guidelines/environmental/appendix/air.html#tableb1>
11. Soldati, G, et al. *Is There a Role for Lung Ultrasound During the COVID-19 Pandemic?* (March 20, 2020) <https://onlinelibrary.wiley.com/doi/10.1002/jum.15284>
12. American Institute of Ultrasound in Medicine *Guidelines for Cleaning and Preparing External and Internal-Use Ultrasound Transducers and Equipment Between Patients as well as Safe Handling and Use of Ultrasound Coupling Gel* (March 27, 2020) <https://www.aium.org/officialStatements/57>
13. Butterfly Network *Cleaning and disinfection* (2020) <https://www.butterflynetwork.com/covid19/cleaning-and-disinfection>
14. World Health Organization *Infection prevention and control during health care when novel coronavirus (nCoV) infection is suspected* (March, 19, 2020) [https://www.who.int/publications-detail/infection-prevention-and-control-during-health-care-when-novel-coronavirus-\(ncov\)-infection-is-suspected-20200125](https://www.who.int/publications-detail/infection-prevention-and-control-during-health-care-when-novel-coronavirus-(ncov)-infection-is-suspected-20200125)
15. World Health Organization *Q&A on infection prevention and control for health care workers caring for patients with suspected or confirmed 2019-nCoV* (March 31, 2020) <https://www.who.int/news-room/q-a-detail/q-a-on-infection-prevention-and-control-for-health-care-workers-caring-for-patients-with-suspected-or-confirmed-2019-ncov>
16. United Kingdom Government Publication *Reducing the risk of transmission of COVID-19 in the hospital setting* (April 10, 2020) <https://www.gov.uk/government/publications/wuhan-novel-coronavirus-infection-prevention-and-control/reducing-the-risk-of-transmission-of-covid-19-in-the-hospital-setting>

17. Tristel Solutions Ltd *Important Customer Notice- Tristel Chlorine Dioxide Efficacy against Viruses, including Coronavirus* (2020)
<https://www.tristel.com/au/news>
18. Internet Book of Critical Care Possible approach to imaging in COVID-19: Possible schema for imaging in patients with respiratory symptoms and suspected COVID-19 (April 30, 2020) https://emcrit.org/ibcc/covid19/#general_approach_to_imaging

APPENDICES

Numerous resources are available discussing clinical management of COVID-19 in regard to use of radiologic imaging. ⁽¹⁸⁾



Ultrasound limitations

- Inability of lung US to detect focal pneumonia/lesions that are deep in the lung and do not extend to pleural surface.
- Sonographic features must be taken in context of clinical signs/comorbidities
- ***Lack of specificity; sonographic features of COVID overlap with other lung conditions, ie pulmonary edema, bacterial pneumonia, ARDS from other conditions.***

Common clinical applications

- Rapid assessment at presentation
- track evolution of disease
- monitor lung recruitment maneuvers
- guide response to prone therapy
- weaning patient from vent
- ECMO
- Facilitate differential diagnosis in setting of similar clinical picture

Operational guidelines: Infection Control

- Consider portable units that can be utilized solely for COVID-19 patients
- Use appropriate disinfectants, remove as much from cart as possible

Common technical recommendations for lung ultrasound imaging

- Single focal point on pleural line
- Transducer selection: Convex (better for B-lines)/linear (better pleura)
- Optimize beam shape for lung surface
- Utilize a Low Mechanical Index
- Avoid using image filters like harmonics, contrast, persistence, compounding to avoid saturation phenomena
- Need highest frame rate possible
- Consider utilization of cine loop/video for dynamic imaging

Scanning techniques and protocols

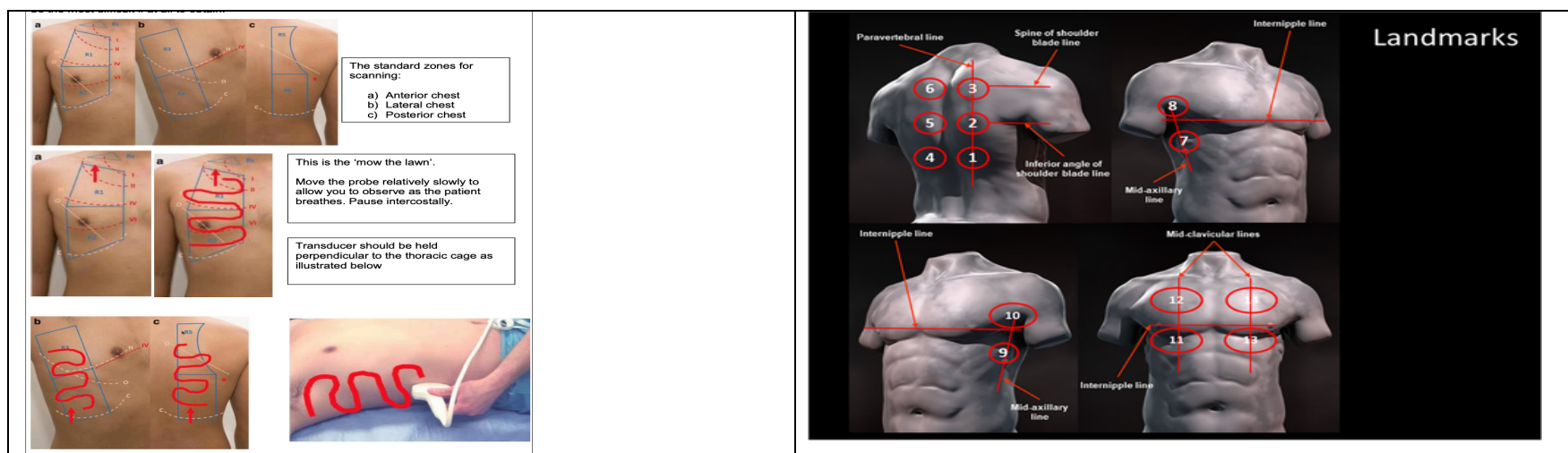
- Intercostal windows for widest surface area

Consider utilizing 10, 12, 14 or 16 window views, posterior views most frequent site of consolidation in COVID-19 pt.'s

Example scanning regions ⁽¹¹⁾

- Anterior midclavicular (apical, medial and basal) right and left
- Posterior paraspinal (apical, medial and basal) right and left
- Lateral axillary (apical and basal) medial right and left

<u>Normal lung ultrasound findings</u>	<u>Findings that can be seen in setting of COVID-19</u>
smooth pleural line, lung slide A-lines	irregular pleural line no A-lines presence of B-lines small to large lung consolidation hepatization of the lung with air bronchograms, depending on disease severity, focal pleural effusions



Modality comparison in setting of COVID-19

Findings related to disease stage, severity of lung injury and comorbidities

Lung CT	Lung ultrasound
Thickened pleura	Thickened pleural line
Ground glass shadow and effusion	B lines (multifocal, discrete, or confluent)
Pulmonary infiltrating shadow	Confluent B lines
Subpleural consolidation	Small (centomeric) consolidations
Translobar consolidation	Both non-translobar and translobar consolidation
Pleural effusion is rare.	Pleural effusion is rare
More than two lobes affected	Multilobar distribution of abnormalities
Negative or atypical in lung CT images in the super-early stage, then diffuse scattered or ground glass shadow with the progress of the disease, further lung consolidation	Focal B lines is the main feature in the early stage and in mild infection; alveolar interstitial syndrome is the main feature in the progressive stage and in critically ill patients; A lines can be found in the convalescence; pleural line thickening with uneven B lines can be seen in patients with pulmonary fibrosis